13 Other Eczematous Eruptions

Norbert Reider and Irina Gasslitter

Chapter Contents

Seborrheic Dermatitis 232
Asteatotic Eczema 235
Disseminated Eczema (Autosensitization) 236
Nummular Dermatitis. 238
Pityriasis Alba 238
HTLV-Associated Infective Dermatitis. 238
Regional Eczematous Disorders 239

In addition to contact and atopic dermatitis, there exists a heterogeneous group of inflammatory skin diseases that obviously share the hallmarks of eczema, but display characteristic additional features. Their pathogenesis is generally less well understood, but most exhibit distinctive etiologic features.

SEBORRHEIC DERMATITIS

Key features

- Infantile and adult forms
- Lesions favor the scalp, ears, face, central chest, and intertriginous areas
- Etiologic links with active sebaceous glands, abnormal sebum composition, and *Malassezia* (*Pityrosporum*) spp.
- Can be a cutaneous sign of HIV infection

Introduction

Seborrheic dermatitis is a common, mild, chronic eczema typically confined to skin regions with high sebum production and the large body folds. Although its pathogenesis is not fully elucidated, there is a link to sebum overproduction (seborrhea), the commensal yeast *Malassezia*, and individual susceptibility.

History

Seborrheic dermatitis was first described by Unna[1], who also suspected *Malassezia furfur* (*Pityrosporum ovale*) as a causative factor. The nosologic position of seborrheic dermatitis was widely discussed for decades, the focus resting on dysfunction of the sebaceous glands and the high amounts of *M. furfur* present in scales of seborrheic dermatitis. In 1984 it was shown that seborrheic dermatitis could be suppressed by systemic ketoconazole[2]. This finding was corroborated by later studies[3], and it became clear that seborrheic dermatitis was strongly linked to these yeasts. Today, it is accepted that several species of *Malassezia*, including *M. furfur*, play a direct role in seborrheic dermatitis (see Table 77.3)[4].

Epidemiology

There are infantile and adult forms, with the former being self-limited and most prevalent the first 3–4 months of life, while the latter is chronic with a peak in the fourth to sixth decades. The prevalence of seborrheic dermatitis is estimated to be 5%, but its lifetime incidence is likely much higher. Men are afflicted more often than women. Extensive and therapy-resistant seborrheic dermatitis is an important cutaneous sign of HIV infection. It is more commonly observed in patients with neurologic diseases (e.g. Parkinson disease, cerebrovascular accidents)[5] or who are immunosuppressed. Additional contributing factors include nutritional deficiencies, impaired epidermal barrier, and occasionally medications (e.g. neuroleptics, atypical antipsychotics). Seborrheic dermatitis-like eruptions have also been reported with dupilumab and antineoplastic agents (e.g. tyrosine kinase inhibitors).

Pathogenesis

Malassezia

The genus *Malassezia* consists of lipophilic yeasts that are part of the normal resident skin flora[6,7]. Studies on the predominance of certain *Malassezia* spp. have revealed conflicting results[8,9]. *M. furfur* may behave as an opportunistic pathogen (e.g. fungemia in neonates receiving intravenous lipid emulsions) or cause or aggravate a spectrum of skin diseases: pityriasis versicolor, *Malassezia (Pityrosporum)* folliculitis, seborrheic dermatitis, and possibly atopic dermatitis.

Malassezia *and seborrheic dermatitis*

M. furfur and related species can be regularly isolated from lesions of seborrheic dermatitis, including infantile seborrheic dermatitis (whereas healthy prepubertal children are not colonized to a significant degree). This coincides with the presence of enlarged sebaceous glands during the neonatal period. There is no simple quantitative relationship between yeast number and severity of seborrheic dermatitis, and unaffected skin may carry a load of organisms similar to seborrheic dermatitis lesions. Even in the scalp, where *M. furfur* predominates amongst the resident flora, only twice as many yeasts may be recovered from areas of seborrheic dermatitis as from normal controls[6]. Amongst patients with AIDS, harboring of *Malassezia* spp. is equivalent, irrespective of the presence or absence of seborrheic dermatitis clinically; however, there is a difference in the amount of yeasts[10].

Active sebaceous glands and seborrheic dermatitis

Seborrheic dermatitis occurs predominantly in areas of the skin with active sebaceous glands and is often associated with sebum overproduction, which in turn can facilitate the growth of *Malassezia*. In infants, sebum is produced for a few weeks after birth, and the adult form of seborrheic dermatitis does not develop before puberty. This argues for a role for sebaceous gland activation by androgens. However, patients with seborrheic dermatitis may have normal sebum production and those with excessive sebum production are often free of seborrheic dermatitis. Thus, the amount of sebum produced alone does not appear to be the decisive risk factor.

It has been proposed that the composition of the skin surface lipids is the relevant factor[11]. In patients with seborrheic dermatitis, triglycerides and cholesterol are elevated but squalene and free fatty acids are significantly decreased. Free fatty acids (which have a known antimicrobial effect) are formed from triglycerides by bacterial lipases produced by the lipolytic *Cutibacterium* (formerly *Propionibacterium*) *acnes*. A major constituent of the resident microbial skin flora, *C. acnes* has been found to be greatly reduced in seborrheic dermatitis[12]. Seborrheic dermatitis may thus be linked to an imbalance of the microbial flora.

Immune responses to Malassezia *in seborrheic dermatitis*

An etiologic role for immune mechanisms against *Malassezia* – particularly in view of the prominence of seborrheic dermatitis in HIV-infected individuals – has been suspected but never convincingly proven. Intrinsic host factors, such as changes in sebum production and a defective epidermal barrier, could favor overgrowth of *Malassezia* spp. which

Downloaded for Anonymous User (n/a) at Egyptian Knowledge Bank from ClinicalKey.com by Elsevier on March 10, 2024. For personal use only. No other uses without permission. Copyright ©2024. Elsevier Inc. All rights reserved.

then incites a host inflammatory response[13]. However, additional studies on cellular immunity have yielded contradictory results[6,7]. The inflammation seen in seborrheic dermatitis might be irritant, caused by toxic metabolites, lipase, and reactive oxygen species[6,13].

Clinical Features

Seborrheic dermatitis is defined by clinical parameters, including:

- sharply demarcated patches or thin plaques that vary from pink–yellow to dull red to red–brown with bran-like to flaky "greasy" scales; vesiculation and crusting may occur but are rare and mostly due to irritation
- a predilection for areas rich in sebaceous glands – scalp, face, ears, presternal region – and, less often, the intertriginous areas
- a mild course with little or moderate discomfort.

Seborrheic dermatitis is most often limited in extent, but generalized and even erythrodermic forms can occur, albeit rarely.

Infantile seborrheic dermatitis

This form usually begins about one week after birth and may persist for several months. Initially, mild greasy scales adherent to the vertex and anterior fontanelle regions arise which may later extend over the entire scalp. Inflammation and oozing may finally result in a coherent scaly and crusty mass covering most of the scalp ("cradle cap"; Fig. 13.1A). Lesions of the axillae, inguinal creases, neck, and retroauricular folds are often acutely inflamed, oozing, sharply demarcated, and surrounded by satellite lesions (Fig. 13.1B). Superinfection with *Candida* spp. or occasionally bacteria (e.g. group A *Streptococcus*) can occur. A disseminated eruption of scaly papules with a psoriasiform appearance ("psoriasiform id reaction") may develop on the trunk, proximal extremities, and face in association with exuberant or superinfected seborrheic dermatitis, especially of the diaper area.

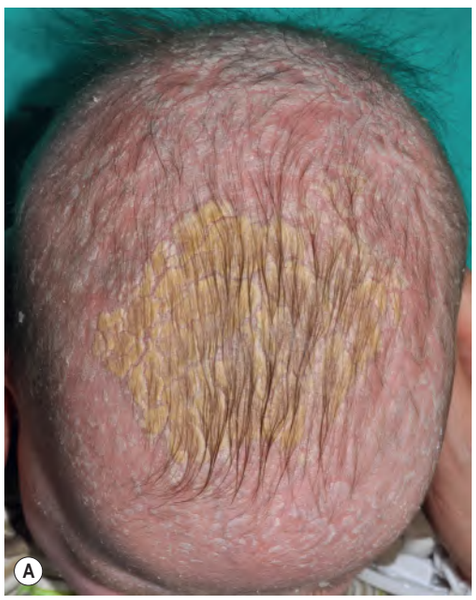

Fig. 13.1 Infantile seborrheic dermatitis. A Involvement of the scalp with thick adherent yellow scale overlying mild inflammation is often referred to as "cradle cap". **B** Glistening red plaques of the neck, axillary and inguinal folds as well as the penis and umbilicus. Note disseminated lesions on the trunk and extremities. *A, Courtesy Antonio Torello, MD; B, Courtesy Robert Hartman, MD.*

Adult seborrheic dermatitis

In adults, seborrheic dermatitis is generally found on the scalp and, usually of milder intensity, on the face; less often, lesions occur on the central upper chest and the intertriginous areas. Erythrodermic seborrheic dermatitis has been described as a rarity.

Pityriasis simplex capillitii (dandruff) is defined as a diffuse, slight to moderate, fine white or greasy scaling of the scalp and terminal hair-bearing areas of the face (beard area), but without significant erythema or irritation. Scales accumulate visibly on dark clothing. This common condition may be considered the mildest form of seborrheic dermatitis of the scalp.

In seborrheic dermatitis of the scalp, there is inflammation and pruritus in addition to dandruff. The vertex and parietal regions are predominantly affected, but in a more diffuse pattern than the discrete plaques of psoriasis. Towards the forehead, the erythema and scaling are usually sharply demarcated from uninvolved skin, with the border either at the hairline or slightly transgressing beyond it. Pruritus is usually moderate but may be intense, particularly in patients with male pattern alopecia; folliculitis, furuncles, and meibomitis are not uncommon complications, elicited by scratching and rubbing.

Seborrheic dermatitis of the facial skin is often strikingly symmetric, affecting the forehead, medial portions of the eyebrows, upper eyelids, nasolabial folds and lateral aspects of the nose, retroauricular areas, and occasionally the occiput and neck (Fig. 13.2). Lesions are yellowish-red, with a typical bran-like scale. Non-purulent otitis externa is often observed. If present, lesions of the trunk are preferentially found in the presternal and intertriginous areas (Fig. 13.3); those on the central chest can have a petaloid appearance. Seborrheic dermatitis, like inverse psoriasis, is a cause of intertrigo (Fig. 13.4).

In patients with seborrheic dermatitis, the skin is sensitive to irritation, and exposure to sun or heat, febrile illnesses, and overly aggressive topical therapy may precipitate flares and dissemination. Rebound flares can also follow tapers of systemic corticosteroids. Seborrheic dermatitis is more common during the winter in patients with skin phototypes I–II, most likely a reflection of increased xerosis and decreased epidermal barrier function[14].

Irritated seborrheic dermatitis lesions can become bright red and erosive. *Malassezia (Pityrosporum)* folliculitis is another complication characterized by pruritic erythematous follicular papules, sometimes pustules, typically in sites rich in sebaceous glands.

Adult seborrheic dermatitis has a chronic relapsing course. Patients feel well and systemic signs are absent. Extensive and severe seborrheic dermatitis, however, should raise the suspicion of underlying HIV infection. Among patients with seborrheic dermatitis tested for HIV infection, 2% were found to be positive, frequently in a late stage of their disease[15]. In patients with Parkinson disease, seborrheic dermatitis is a common finding, along with seborrhea. Its severity, however, is not correlated with that of the Parkinson disease[16]. The facial immobility of patients with Parkinson disease might result in a greater accumulation of sebum on the skin, resulting in a permissive effect on the growth of *Malassezia*[16,17]. Seborrheic dermatitis may also be more common in patients with other causes of immobility such as cerebrovascular accidents.

Pathology

Acute seborrheic dermatitis displays spongiosis with a superficial perivascular and perifollicular lymphocytic infiltrate composed mainly of lymphocytes. Older lesions show irregular acanthosis and focal parakeratosis. The latter may appear similar to psoriasis, but exocytosis of neutrophils, Munro microabscesses, and confluent parakeratotic horny layers are absent.

Differential Diagnosis

Infantile seborrheic dermatitis is distinguished from *atopic dermatitis* by its earlier onset, different distribution pattern, and, most importantly, by the absence of pruritus, irritability, and sleeplessness. In contrast to

Downloaded for Anonymous User (n/a) at Egyptian Knowledge Bank from ClinicalKey.com by Elsevier on March 10, 2024. For personal use only. No other uses without permission. Copyright ©2024. Elsevier Inc. All rights reserved.

Fig. 13.2 Adult seborrheic dermatitis of the face, ear and scalp. A Rather sharply demarcated pink plaque with flaky white and greasy scale. Note the fissure in the retroauricular sulcus. **B** Sharply demarcated pink–orange thin plaques with yellow, greasy scale, especially in the nasolabial fold. When this degree of severity is seen, the possibility of underlying HIV infection needs to be considered. **C** Symmetric red–brown to violet plaques of the central forehead, nasal bridge, and medial cheeks with an associated hypopigmented peripheral and figurate rim. **D** Involvement of the upper eyelids, medial canthal regions, and infraorbital creases; seborrheic dermatitis confined to the major crease in the outer canthal region can also be seen. *C, Courtesy Jeffrey P. Callen, MD; D, Courtesy Kalman Watsky, MD.*

Fig. 13.3 Seborrheic dermatitis of the presternal region in an adult. It sometimes resembles the petals of a flower.

atopic dermatitis, infants with seborrheic dermatitis generally feed well and are content. *Irritant diaper dermatitis* is confined to the diaper area and tends to spare the skin folds (see below). *Candidiasis* of the diaper area can result from colonization with fecal yeast and some infants have seborrheic dermatitis with a superimposed candidal infection. The differential diagnosis also includes *streptococcal intertrigo* (see Fig. 13.12). *Infantile psoriasis* may be difficult to distinguish from psoriasiform seborrheic dermatitis. Although psoriasiform diaper dermatitis can represent the initial manifestation of psoriasis, many affected infants do not subsequently develop psoriasis elsewhere.

Rare conditions to be considered are Langerhans cell histiocytosis, "nutritional dermatitis" (e.g. acrodermatitis enteropathica; see Fig. 51.13), and Leiner disease. The last-mentioned is a questionable entity, once thought to be the maximal variant of infantile seborrheic dermatitis, but nowadays viewed as erythroderma in the setting of underlying immunosuppression (see Chs. 10 & 60).

When scalp scaling is present in prepubertal, especially Black, children, the possibility of *tinea capitis* due to *Trichophyton tonsurans* should be considered. In *pityriasis amiantacea*, thick asbestos-like scales adhere to tufts of scalp hairs; up to a third of the affected children and adolescents eventually develop psoriasis.

A number of entities are included in the differential diagnosis of **adult** seborrheic dermatitis. Distinction of seborrheic dermatitis *of the scalp* from psoriasis can be difficult, and there may be an overlap in some patients ("sebopsoriasis"). However, the plaques of psoriasis tend to be thicker, with silvery white scale, more discrete, less pruritic, and unassociated with seborrhea. In addition, features of psoriasis may be found elsewhere. Dry scaling of the scalp, along with dry brittle hair (as opposed to greasy hair), is a symptom of xerotic skin (e.g. in atopic dermatitis), frequently mistaken for (and mistreated as) seborrheic dermatitis. Mild erythema and scale of the posterior scalp, often with demonstrable hair loss, can be seen in dermatomyositis[18].

Seborrheic dermatitis *of the face* may closely resemble both early rosacea and the butterfly lesions of systemic lupus erythematosus. Lupus erythematosus rarely affects the nasolabial folds and often has a clearly demonstrable photodistribution. Notably, seborrheic dermatitis and rosacea frequently coexist. The facial dermatitis seen in patients receiving dupilumab may resemble seborrheic dermatitis. The differential diagnosis of seborrheic dermatitis *of the trunk* includes pityriasis rosea (but in this latter entity the lesions are ellipsoid in shape, have collarette-like scaling, and there is no predilection for the central chest) as well as superficial eruptive psoriasis and subacute cutaneous lupus erythematosus.

Seborrheic dermatitis *of the intertriginous areas* must be distinguished from inverse psoriasis, erythrasma, intertriginous dermatitis, candidiasis, and, rarely, Langerhans cell histiocytosis (see Fig. 13.4).

Downloaded for Anonymous User (n/a) at Egyptian Knowledge Bank from ClinicalKey.com by Elsevier on March 10, 2024. For personal use only. No other uses without permission. Copyright ©2024. Elsevier Inc. All rights reserved.

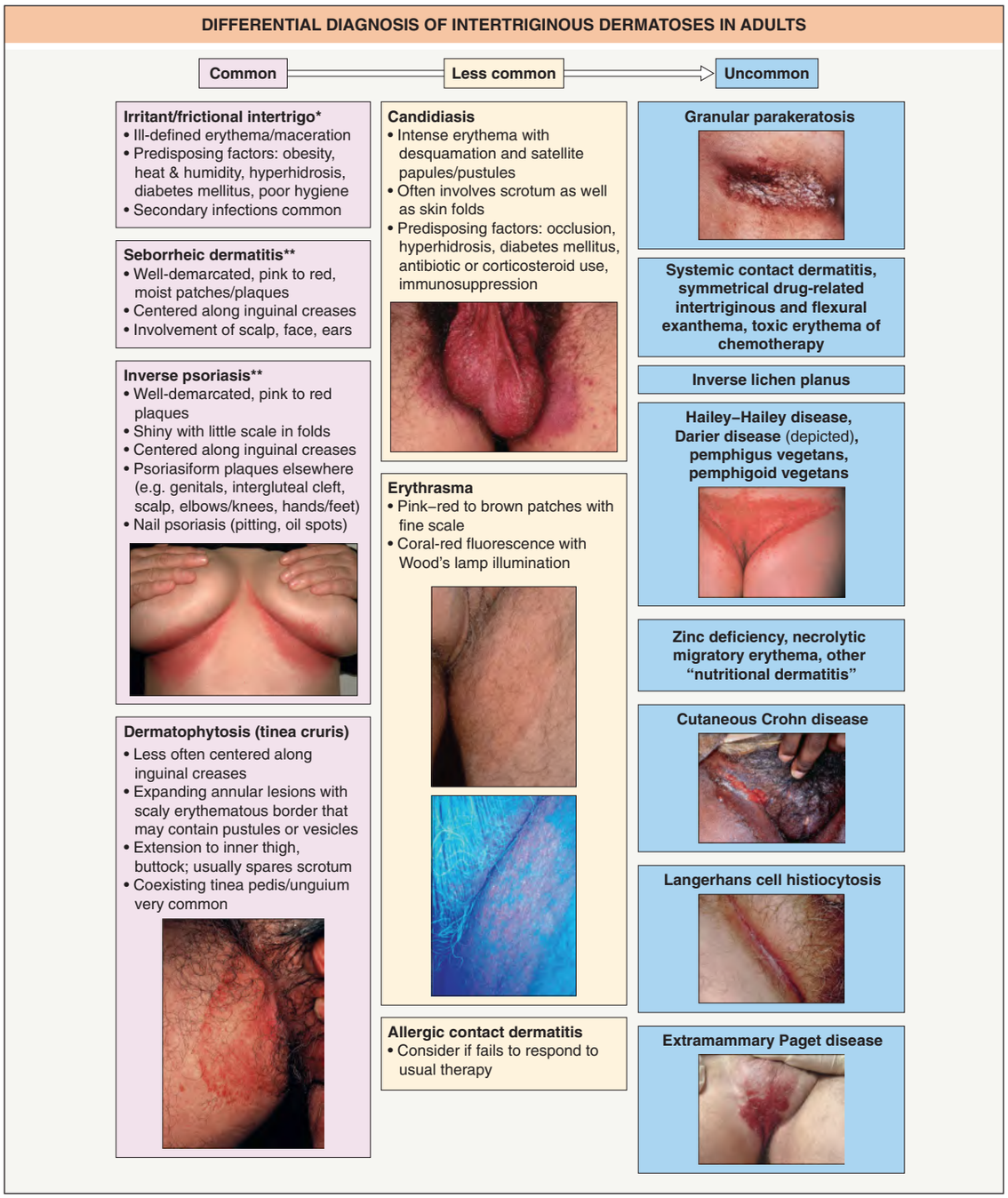

Fig. 13.4 Differential diagnosis of intertriginous dermatoses in adults. Individual patients often have multiple disorders superimposed upon one another. Bullous impetigo and streptococcal intertrigo are considerably more common in children than adults. *Also referred to more nonspecifically as intertriginous dermatitis or intertrigo. **The term "sebopsoriasis" may be used when features of both seborrheic dermatitis and psoriasis are present. *Insets: Courtesy Luis Requena, MD; Eugene Mirrer, MD; Louis A. Fragola, Jr, MD; David Mehregan, MD; Julie V. Schaffer, MD.*

Treatment

Infantile seborrheic dermatitis

Infantile seborrheic dermatitis usually responds satisfactorily to bathing and application of emollients. Ketoconazole cream (2%) is indicated in more extensive or persistent cases[19]. Short courses of low-potency topical corticosteroids may be used initially to suppress inflammation. Mild shampoos are recommended for the removal of scalp scales and crusts. Avoidance of irritation (e.g. the use of strong keratolytic shampoos or mechanical measures to remove the scales from the scalp) is important.

Adult seborrheic dermatitis

The mainstay of therapy is the use of topical azoles (e.g. ketoconazole), either as shampoos (scalp) or as creams (body). The high response rate (75%–90%) of this treatment has been documented in double-blind trials[3]. Ciclopirox olamine has antifungal and anti-inflammatory activities and has also been shown to be effective as a shampoo or cream in double-blind, randomized trials. Seborrheic dermatitis tends to relapse if a maintenance regimen is not instituted. As *M. furfur* has a slow proliferation rate, an interval of two to several weeks will pass until relapses appear. The intervals of topical therapy should follow this rhythm.

Additional measures, particularly in the initial stages of treatment, include emollients and low-potency topical corticosteroids; the latter were found to be equally efficacious as topical azoles in a Cochrane analysis[20]. Second-line treatment options include zinc pyrithione, selenium sulfide, and tar shampoos as well as topical calcineurin inhibitors. Systemic antimycotics (e.g. weekly fluconazole) should only be used in cases of severe findings or frequent recurrences.

ASTEATOTIC ECZEMA

Synonyms: ▪ Eczema craquelé ▪ Winter eczema ▪ Winter itch ▪ Desiccation dermatitis

Downloaded for Anonymous User (n/a) at Egyptian Knowledge Bank from ClinicalKey.com by Elsevier on March 10, 2024. For personal use only. No other uses without permission. Copyright ©2024. Elsevier Inc. All rights reserved.

Key features

- Dry, rough, scaly, and inflamed skin with superficial cracking that resembles a "dried riverbed"
- Sites of predilection are the shins, lower flanks, and posterior axillary line
- Associated with aging, xerosis, low relative humidity, and frequent bathing

Introduction

Dry skin (xerosis, asteatosis, exsiccosis) may result from both exogenous and endogenous causes: a dry climate or low indoor humidity; excessive exposure to water, soaps, and surfactants; marasmus and malnutrition; chronic kidney diseases and hemodialysis; hypothyroidism; HIV infection; and heritable conditions such as ichthyosis vulgaris and atopic dermatitis. Asteatotic eczema also arises in patients with reduced sweat gland function (e.g. chronic graft-versus-host disease) or in sites of edema due to hypoalbuminemia from hepatic cirrhosis or nephrotic syndrome. That said, the most common cause of xerosis is aging. Rarely, but especially when widespread and refractory to therapy, asteatotic eczema may be related to an underlying neoplasm, including lymphoma[21].

History and Epidemiology

Asteatosis as the cause of "nummular eczema" was first mentioned by Gross[22] in the late 1940s. Dry skin probably occurs in everyone over the age of 60 years, but its severity is strongly linked to the exogenous and endogenous factors mentioned above.

Pathogenesis

Xerosis of aging skin is not caused by deficient sebum production, but by a complex dysfunction of the stratum corneum (see Ch. 124)[23]. There is a decrease of intercellular lipids with a deficiency of all key stratum corneum lipids[24] and an altered ratio of esterified fatty acids to ceramide 1[25]; this, plus a persistence of corneodesmosomes[26] and premature expression of involucrin and formation of the cornified envelope[27], results in corneocyte retention and marked impairment of barrier recovery[24]. The water-binding capacity of the stratum corneum is reduced owing to decreased synthesis of "natural moisturizing factor" (NMF) as well as decreased intercellular lipids and glycerol content[28]. Consequently, the stratum corneum desiccates, loses its pliability, and forms small cracks, which render the skin surface dull, rough, and scaly.

Mild xerosis is asymptomatic, but if more pronounced, the skin conveys unpleasant sensations such as pruritus and stinging. Inflammation is enhanced by the release of proinflammatory cytokines secondary to barrier perturbation, mechanical factors (scratching, rubbing), and the application of irritating or sensitizing substances in topical preparations and skin care products.

Occasionally, eczema craquelé can appear in the setting of acute edema[29], e.g. from congestive heart failure or the re-feeding of patients with anorexia nervosa. One theory is that this is related to the rate of distention of the skin.

Clinical Features

Xerosis first arises on the shins. Later it may spread to the proximal extremities and trunk, but spares the face and neck as well as the palms and soles. It develops insidiously over many years, whereas asteatotic eczema often has a more subacute to acute onset.

Xerotic skin is dry and dull, with fine bran-like scales that may be released as powdery clouds when patients take off their stockings. If more advanced, the skin exhibits a criss-cross pattern of superficial cracks and fissures of the horny layer ("crazy-paving", eczema craquelé, "dried riverbed") and appears pink to light red in color (Fig. 13.5). The skin becomes rough, and it may develop an appearance similar to ichthyosis vulgaris ("pseudo-ichthyosis"). In more advanced stages of asteatotic eczema, there is a dull erythema as well as oozing, crusting, and abundant excoriations; disseminated nummular lesions are frequently seen. Vesiculation and lichenification are not regular features except when irritant or allergic contact dermatitis is superimposed. Hemorrhage into the fissures is occasionally observed.

Fig. 13.5 Asteatotic eczema (eczema craquelé). A On the shins, a criss-cross pattern of superficial cracks, fissures, and hemorrhagic crusts said to resemble a dried riverbed. **B** Xerosis with adherent white scales (pseudo-ichthyosis) and inflammation as well as the criss-cross pattern of superficial cracks and fissures.
A, Courtesy Kalman Watsky, MD; B, Courtesy Louis A. Fragola, Jr, MD.

Pathology

Histologically, xerotic skin appears rather normal except for a compact and slightly irregular stratum corneum. Asteatotic eczema in addition exhibits mild focal spongiosis, focal parakeratosis, and a sparse inflammatory infiltrate in the superficial dermis.

Differential Diagnosis

Conditions that need to be distinguished from asteatotic eczema include stasis dermatitis, adult atopic dermatitis (which may overlap with asteatotic eczema), allergic contact dermatitis, nummular dermatitis, and scabies.

Treatment

Asteatotic eczema usually clears within a few days of the application of topical corticosteroid ointment. Proper attention must be given to the care of xerosis in order to avoid relapses: regular use of petrolatum, water-in-oil emollients, urea-, ceramide- or lactic acid-containing preparations, use of bath oils, and the elimination of factors that aggravate dry skin (see above). Topical calcineurin inhibitors have also been used. Coexisting stasis dermatitis should be treated as well (see below).

DISSEMINATED ECZEMA (AUTOSENSITIZATION)

Synonyms: ▪ Autosensitization dermatitis ▪ Autoeczematization ▪ Generalized eczema ▪ Id reaction

Downloaded for Anonymous User (n/a) at Egyptian Knowledge Bank from ClinicalKey.com by Elsevier on March 10, 2024. For personal use only. No other uses without permission. Copyright ©2024. Elsevier Inc. All rights reserved.

Key features

- Secondary lesions of eczema distant from the primary site of exposure or involvement
- Symmetric distribution pattern
- Most often associated with allergic contact dermatitis and stasis dermatitis

Introduction

Dermatitis caused by exogenous agents initially arises at the site of contact. Not infrequently, additional patches of eczema develop at distant sites. This phenomenon, termed secondary dissemination, has puzzled dermatologists for decades. It is most often observed in allergic contact dermatitis, particularly if associated with stasis dermatitis (see Fig. 13.8), but may occur with uncomplicated stasis dermatitis, other forms of eczema, and, occasionally, severe tinea pedis.

Disseminated eczema appears later than the primary lesions by a few days to weeks, tends to follow a strikingly symmetric distribution pattern, and shows a predilection for analogous anatomic sites (e.g. extensor aspects of the lower and upper extremities, palms, and soles). It may even arise in the absence of and without a preceding "primary" eczema, e.g. in nummular dermatitis (see below). Disseminated eczema must be distinguished from atopic dermatitis, which arises *a priori* in a disseminated fashion.

History and Pathogenesis

The phenomenon of secondary dissemination of eczemas was first described by Whitfield[30], but its pathogenesis is still not fully elucidated. The orderly and symmetric distribution pattern may reflect systemic (hematogenous) dissemination and argues against simple spread of contact irritants or allergens on the body surface. It is unclear, however, as to exactly what is disseminated via the bloodstream. It could be allergens; for example, the ingestion of allergens such as nickel has been shown to elicit disseminated eczema in sensitized individuals[31,32].

Hematogenous dissemination of microbial products leading to a variety of (non-infectious) manifestations distant from the site of infection, such as "tuberculids" and "bacterids", was an accepted pathogenic model in the first half of the twentieth century and was extrapolated to the phenomenon of disseminated eczema. Dyshidrotic eczema of the soles, for example, was interpreted as an "id" reaction associated with tinea pedis, and nummular eczema as an "id" reaction caused by "focal" infections of the tonsils. Because disseminated eczema could hardly be attributed solely to infections, attention shifted to an "autosensitization" to epidermal antigens mediated by cytotoxic autoantibodies. This hypothesis, however, has never been verified.

Instead, it became clear both from animal experiments[33] and from routine patch testing ("excited skin syndrome", "angry back")[34,35] that inflammatory processes of the skin, both allergic and irritant or caused by infections, lower the irritancy threshold of distant skin and thus facilitate the development of an eczematous reaction. Obviously, circulating activated memory T cells may play an additional role in disseminated eczema associated with allergic contact dermatitis, including that seen with rebound poison ivy dermatitis following a short, rapid taper of systemic corticosteroids. It remains to be determined which factors regulate the symmetric distribution of disseminated eczema.

Epidemiology

An estimated two-thirds or more of patients with contact dermatitis associated with stasis dermatitis develop episodes of disseminated eczema. The incidence is much lower in the other types of eczema or tinea pedis.

Clinical Features

Disseminated eczema associated with allergic contact dermatitis is characterized by moderately to poorly demarcated patches of eczema, most often on the extremities (Fig. 13.6A). Lesions are also found on the face, and less so on the trunk (Fig. 13.6B). The areas of involvement vary greatly in size and number and may consist of discrete papules which are often excoriated. Disseminated eczema in patients with seborrheic and asteatotic eczema differs slightly in predilection sites and morphology (see above).

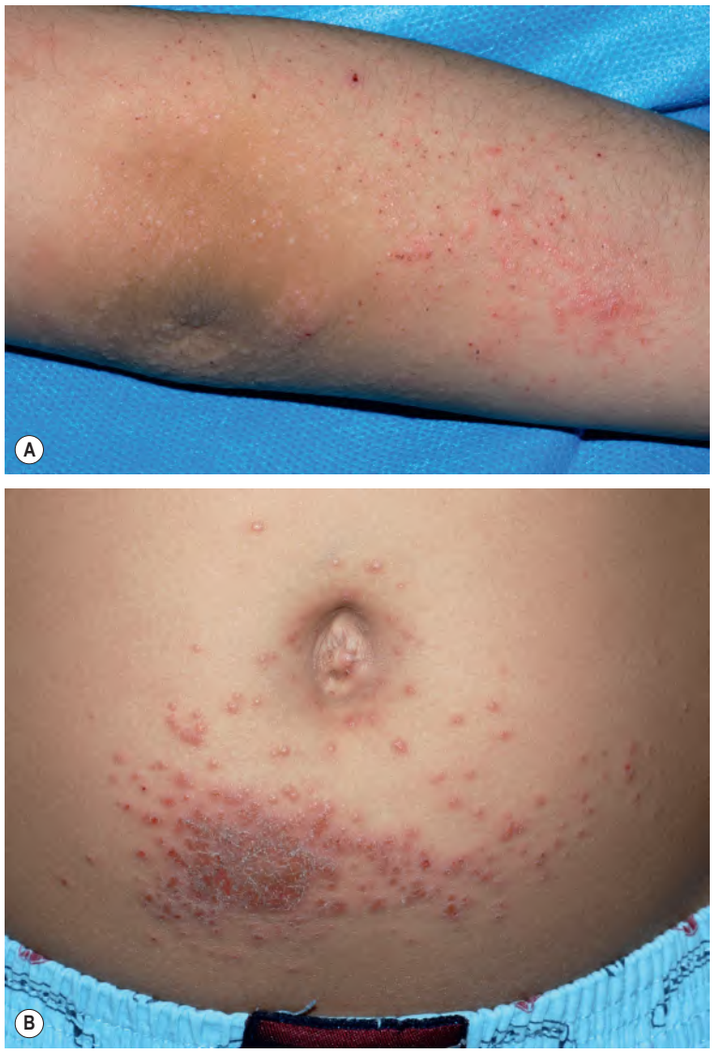

Fig. 13.6 Id reactions in children due to allergic contact dermatitis (ACD) to nickel. A Multiple flat-topped papules, several of which have been excoriated, in addition to patches of eczema. **B** Square-shaped area of ACD due to nickel in a buckle with an associated id reaction. The latter consists of edematous crusted papules that are separate from the area of direct nickel contact. *Courtesy Julie V. Schaffer, MD.*

Pathology

In biopsy specimens of disseminated eczema, the histologic findings are those of an acute or subacute eczematous dermatitis (see section "Stasis dermatitis").

Differential Diagnosis

Conditions to be distinguished are those eczemas that can arise in a widespread or disseminated fashion: atopic dermatitis, airborne contact dermatitis, contact dermatitis caused by constituents of textiles, photoallergic dermatitis, and eczematous drug eruptions (e.g. calcium channel blockers). Other conditions to be considered are mycosis fungoides and Sézary syndrome.

Treatment

Topical corticosteroids and systemic antihistamines are the mainstay of therapy. Short courses of systemic corticosteroids may be required, but identification and aggressive topical treatment of the inciting dermatosis is necessary to help prevent recurrences or a rebound flare.

Downloaded for Anonymous User (n/a) at Egyptian Knowledge Bank from ClinicalKey.com by Elsevier on March 10, 2024. For personal use only. No other uses without permission. Copyright ©2024. Elsevier Inc. All rights reserved.

NUMMULAR DERMATITIS

Synonyms: ▪ Nummular eczema ▪ Discoid eczema ▪ Microbial eczema

Key features

- Coin-shaped, disseminated, eczematous lesions
- Usually very pruritic
- Chronic course

Introduction

Nummular dermatitis is an uncommon, disseminated eczema characterized by its coin-shaped lesions. Because such lesions can occur as a feature of atopic dermatitis, asteatotic eczema, and stasis dermatitis, the nosologic position of nummular dermatitis as an independent clinical entity has been questioned.

Epidemiology

Nummular lesions of eczema are not uncommon. However, in the literature there are widely discrepant data on the prevalence of nummular dermatitis, ranging from 0.1% to 9.1%[36]. Some of this variability may reflect the degree to which a distinction is made between nummular dermatitis and coin-shaped lesions observed in patients with other forms of eczema. Men are affected slightly more often and at a later age than women (>50 vs <30 years, respectively).

Pathogenesis

Nummular lesions of dermatitis are not infrequently associated with contact sensitization as well as with xerosis and venous hypertension. In a study of ~30 000 consecutive patients with different types of eczema who underwent patch testing, 3.5% were diagnosed as having nummular dermatitis; 32.5% of these individuals had at least one positive patch test reaction, most often to nickel sulfate, potassium dichromate, and cobalt chloride[36]. Clinical and laboratory signs of atopy are absent in "true" nummular dermatitis.

Clinical Features

Nummular dermatitis is defined as an eruption of round (discoid) eczematous patches almost exclusively of the extremities, often the lower legs in men and the forearms and dorsal aspects of the hands in women (Fig. 13.7A)[36]. The lesions are well demarcated and measure 1–3 cm, only occasionally being larger (Fig. 13.7B,C). They may be acutely inflamed with vesicles and weeping, but are often lichenified and hyperkeratotic. Pruritus may be intense and excoriations are often prominent. Nummular dermatitis usually takes a very chronic course. A particularly therapy-resistant variety has been termed "oid-oid" disease, also referred to as exudative discoid and lichenoid chronic dermatitis or Sulzberger–Garbe syndrome.

Pathology

Histologically, the changes of subacute to chronic eczematous dermatitis are seen (Fig. 13.7D; see section "Stasis dermatitis").

Differential Diagnosis

Nummular dermatitis must be distinguished from nummular lesions of atopic dermatitis and dissemination secondary to contact dermatitis or stasis dermatitis. Other conditions to be considered are psoriasis, inflammatory tinea corporis, mycosis fungoides, and Bowen disease.

Treatment

Options include medium- to high-potency topical corticosteroid ointments, topical tacrolimus or pimecrolimus, and emollients. Tar preparations have also been used successfully. However, a number of patients will require phototherapy to clear the lesions. Methotrexate has led to long-term improvement in children, and dupilumab is a therapeutic option for recalcitrant disease[37].

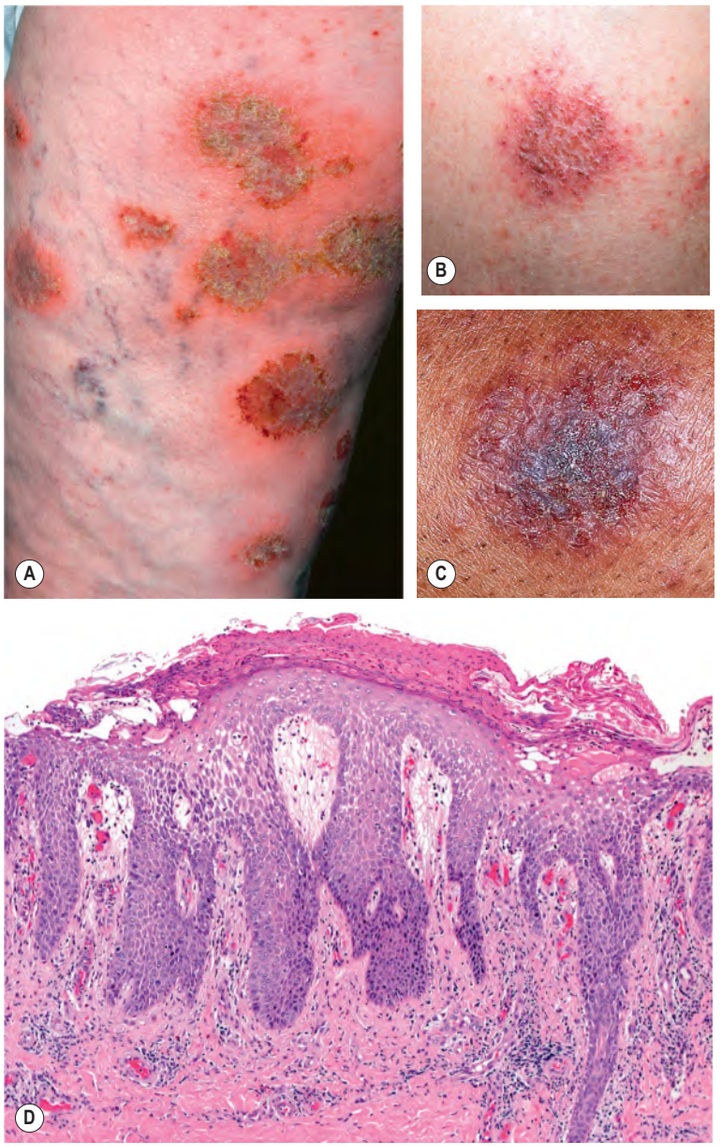

Fig. 13.7 Nummular dermatitis – clinical and histopathologic features. A Multiple coin-shaped lesions of acute and subacute dermatitis on the leg that are fairly well demarcated. There is often marked pruritus. **B, C** Coin-shaped eczematous plaques with scale-crust in two patients with different skin phototypes. Patients may report oozing of lesions. **D** Irregular acanthosis of the epidermis is accompanied by marked spongiosis as well as parakeratotic scale and crust. A lymphohistiocytic infiltrate is present in the dermis with a few lymphocytes within the epidermis. Edema is present in the papillary dermis. *B, C, Courtesy Kalman Watsky, MD; D, Courtesy Lorenzo Cerroni, MD.*

PITYRIASIS ALBA

See Chapter 12.

HTLV-ASSOCIATED INFECTIVE DERMATITIS

Key features

- Rare dermatologic disorder of childhood and adolescence
- Association with human T-cell lymphotropic virus type I (HTLV-1)
- Eczema of the scalp, axillae, and groin; watery discharge of the nose
- Prompt response to antibiotics

Downloaded for Anonymous User (n/a) at Egyptian Knowledge Bank from ClinicalKey.com by Elsevier on March 10, 2024. For personal use only. No other uses without permission. Copyright ©2024. Elsevier Inc. All rights reserved.

Introduction and Pathogenesis

Human T cell lymphotropic virus type I (HTLV-1), also referred to as human T cell leukemia virus type I and adult T cell lymphoma virus type 1, was first detected in 1980[38], and it can infect T cells, B cells, and monocytes. HTLV-1 is transmitted primarily via breastfeeding, but also by sexual intercourse, blood transfusion, and needle sharing in intravenous drug users. It has been associated with adult T cell leukemia/lymphoma (ATLL), myelopathy/tropical spastic paraparesis, and infective dermatitis. Presumably, HTLV-1-induced dysregulation of the immune system leads to immunosuppression and subsequent infections with *Staphylococcus aureus* or β-hemolytic streptococci[39]. There is also a potential role for genetic factors, low socioeconomic status, and malnutrition.

The activity of HTLV-1 in infected subjects appears to be low – more than 90% of carriers remain asymptomatic[40] and the majority of disease symptoms (other than infective dermatitis) emerge during adulthood. HTLV-1 induces spontaneous T cell proliferation independent of exogenous stimuli, followed by interleukin (IL)-2 receptor expression (CD25), increased IL-2 secretion, and induction of interferon-γ, IL-5, and IL-10. In symptomatic patients, levels of tumor necrosis factor and IL-6 are elevated[41]. In addition to bacterial infections, affected individuals are more susceptible to parasitoses such as scabies and strongyloidiasis[42].

History and Epidemiology

Major endemic areas of HTLV-1 infection include sub-Saharan Africa, northern South America, the Caribbean basin, southern Japan, and Iran, affecting 10–20 million people worldwide. Infective dermatitis was first described in 1966 by Sweet[43], and a year later Walshe[44] suggested an underlying immune defect was present because relapses of the dermatitis frequently occurred, even after a prompt initial response to antibiotic treatment. In 1990, the association with HTLV-1 was first reported[39]. The probability of developing infective dermatitis was estimated to be 2% amongst HTLV-1-infected children[45], with cutaneous manifestations typically appearing only after protective maternal antibodies had disappeared.

Clinical Features

Infective dermatitis presents as an exudative and crusty eczematous dermatosis, affecting primarily the head and neck region, including the scalp, ears, eyelid margins, and paranasal skin, as well as the axillae and groin[40]. A generalized fine papular rash is occasionally observed and there is usually secondary infection with *Staphylococcus aureus* or β-hemolytic streptococci. Complications include parasitic infestations, corneal opacities, and progression to more severe HTLV-1-associated disorders (e.g. ATLL). Infective dermatitis rarely persists into adulthood. However, in a series of adult patients in Bahia with HTLV-1-associated ATLL, 44% had a history of infective dermatitis[46]. Diagnosis is established by major and minor criteria (Table 13.1)

CRITERIA FOR THE DIAGNOSIS OF HTLV-ASSOCIATED INFECTIVE DERMATITIS
Major
• Eczema of the head and neck region, including the scalp, ears, eyelid margins, and paranasal skin, as well as the axillae and groin
• Chronic watery nasal discharge and/or crusting of the anterior nares
• Chronic relapsing dermatitis which responds quickly to antibiotics but relapses promptly after withdrawal
• Onset during early childhood
• **Seropositivity for HTLV-1**
Minor
• Positive cultures for *Staphylococcus aureus* and/or β-hemolytic streptococci from the skin or anterior nares
• Generalized fine papular rash
• Anemia, elevated erythrocyte sedimentation rate
• Hyperimmunoglobulinemia
• Elevated $CD4^+$ and $CD8^+$ T cell counts; elevated CD4/CD8 ratio

Table 13.1 Criteria for the diagnosis of HTLV-associated infective dermatitis. To establish the diagnosis, four major criteria are required, with mandatory inclusion of human T-cell lymphotropic/leukemia virus type I (HTLV-1) seropositivity. For the first major criterion, the involvement of at least two body regions is required. *Adapted from La Grenade L, Manns A, Fletcher V, et al. Clinical, pathologic, and immunologic features of human T-lymphotrophic virus type I-associated infective dermatitis in children. Arch Dermatol 1998;134:439–44.*

Differential Diagnosis

The major entity in the differential diagnosis is atopic dermatitis. Apart from serologic evidence of HTLV-1 infection, lesions of infective dermatitis are more exuberant and obviously infected, but pruritus is less intense. Crusting of the nasal vestibule and blepharoconjunctivitis are more prominent than in atopic dermatitis. Furthermore, it is not associated with atopy. Other disorders to consider include seborrheic dermatitis and impetigo.

Treatment

Antibiotics (e.g. sulfamethoxazole–trimethoprim, cephalexin, erythromycin) result in improvement of the skin lesions but do not prevent relapses. Topical treatments include antibiotics (including intranasal), corticosteroids, and bleach baths.

REGIONAL ECZEMATOUS DISORDERS

Stasis Dermatitis

Synonyms: ▪ Gravitational dermatitis ▪ Varicose eczema ▪ Congestion eczema

Key features

- Often associated with other signs of venous hypertension
- Can be complicated by allergic contact dermatitis
- One of the most common causes of disseminated eczema (autosensitization dermatitis)

Introduction

Stasis dermatitis is a common component of the clinical spectrum of chronic venous insufficiency of the lower extremities (see Ch. 105). It may arise as an early sign of chronic venous insufficiency, but can persist or recur throughout all stages and is often most prominent when ulcers are present. There is little doubt that chronic venous hypertension *per se* is the initial trigger for stasis dermatitis[47]. Over time, additional etiological factors may act in concert, most importantly contact sensitization to ingredients of topical therapies. Stasis dermatitis is one of the most common causes of secondary dissemination of dermatitis, and is therefore a complex and multifactorial condition.

History

The term "stasis dermatitis" was introduced by Pillsbury[48], and the term "gravitation dermatitis" by Belisario[49].

Epidemiology

The prevalence of chronic venous insufficiency is variable among different ethnic groups and societies. In Central Europe, ~15% of the adult population has symptoms of chronic venous insufficiency and about 1% suffers from venous ulcers. Prevalence rates clearly rise with age.

Pathogenesis

Venous hypertension of the lower limbs is linked to the upright position and is caused by multiple factors, most importantly valvular incompetence of the deep leg veins (see Fig. 105.2). With venous hypertension, there is a slowing of blood flow within the microvasculature, distension of capillaries, and damage to the capillary permeability barrier, allowing the passage of fluid and plasma proteins into the tissue (edema) and extravasation of erythrocytes (stasis "purpura" and hemosiderin deposition). These processes lead to microangiopathy, with serious consequences (Table 13.2)[58].

Both microangiopathy and chronic inflammation are likely to be responsible for stasis dermatitis. Stasis dermatitis typically occurs in the same (i.e. the medial supramalleolar) regions where microangiopathy is most intense, and the patches of dermatitis arise preferentially

Downloaded for Anonymous User (n/a) at Egyptian Knowledge Bank from ClinicalKey.com by Elsevier on March 10, 2024. For personal use only. No other uses without permission. Copyright ©2024. Elsevier Inc. All rights reserved.

PATHOGENETIC FACTORS IN STASIS DERMATITIS	
Factor	**Consequence**
Chronic venous insufficiency and the microvasculature	
Deposition of proteins, particularly fibrin, around vessels as hyaline cuffs	• Deposits inhibit oxygen diffusion and metabolic exchange in combination with interstitial edema
Slow blood flow	• Upregulation of ICAM-1 and VCAM-1 on endothelia[50] • Activation of neutrophils and macrophages[51] • Expression of L-selectin on neutrophils[52] • Neutrophils attracted into and trapped within affected areas, notably the medial supramalleolar region[53]
Release of inflammatory mediators, free radicals, and proteases by neutrophils	• Pericapillary inflammation
Free iron ions released from hemosiderin deposits	• Increase in free radical production and lipid peroxidation • Activation of matrix metalloproteinases[54]
Platelet accumulation within the microvasculature	• May trigger focal thrombosis
Fibrosis and tissue remodeling due to imbalances within the capillary network	• Lipodermatosclerosis – dermal sclerosis and septal sclerosis that present as sclerosing panniculitis • Lymphatic dysfunction • "Atrophie blanche" – stellate sclerotic areas depleted of capillaries with the formation of peripheral giant capillaries • May lead to the formation of venous ulcers
Elevated plasma levels of homocysteine[55]	• Hyperhomocysteinemia is associated with an increased risk of thromboses
Complicating factors	

Allergic contact dermatitis	• Sensitizers are often in topical agents used to combat pruritus, xerosis, and presumed infection[56,57]
	  • Antibiotics, e.g. bacitracin, neomycin
	  • Lanolin derivatives
	  • Corticosteroids
	  • Fragrances, e.g. Balsam of Peru
	  • Preservatives
	  • Emulsifiers
	  • Antiseptics, e.g. iodine*
	  • Chemicals of plant origin, rubber in pressure stockings
	  • Wound dressing components
	• Patients with chronic venous insufficiency often exhibit multiple contact allergies

Irritant contact dermatitis	• The exudate from draining ulcers leads to maceration, increased inflammation, and bacterial colonization of surrounding skin • Infectious eczematous dermatitis may occur

*More commonly, irritant contact dermatitis.

Table 13.2 Pathogenetic factors in stasis dermatitis. See Fig. 105.3.

over dilated varicose veins. Also, dermal inflammation is known to induce epidermal dysfunction, including barrier impairment.

Sometimes, patients report intense pruritus that even develops before the eczema. Pruritus may be caused by repeated congestion and decongestion, as well as by the release of inflammatory mediators within the dermis. Scratching or rubbing worsens and perpetuates the dermatitis. In addition, patients often apply topical agents to combat the pruritus and xerosis, increasing the risk of contact dermatitis (see Table 13.2).

Clinical features

The first sign of chronic venous insufficiency is usually a cushion-like pitting edema of the medial aspects of the shin and calf around and proximal to the ankle, corresponding to the location of the major communicating veins (Table 13.3). Edema is more pronounced in the evening and resolves overnight. Bouts of stasis purpura lead to areas of hemosiderin deposition. At this stage, stasis dermatitis is mild or absent; the skin may be dry and pruritic. Later, the edema extends to the distal third of the calf and subfascial edema arises, often accompanied by inflammation which may mimic cellulitis (acute lipodermatosclerosis; "pseudoerysipelas"). Over a period of years, the skin, subcutaneous adipose tissue, and deep fascia become progressively indurated and mutually adherent (chronic lipodermatosclerosis). A firm circular cuff is formed which appears to strangle the distal calf, creating an inverted wine bottle appearance. The skin may show intense hemosiderin pigmentation and changes of atrophie blanche. In this setting, venous ulcers develop spontaneously or are triggered by scratching or other trauma. They arise most often in the supramalleolar region, but may later expand (see Ch. 105).

CUTANEOUS SIGNS OF CHRONIC VENOUS HYPERTENSION
• Edema, often tender • Varicosities, including venulectasias of the instep • Petechiae superimposed on a yellow–brown discoloration due to hemosiderin deposits (stasis purpura) • Stasis dermatitis • Lipodermatosclerosis, acute and chronic • Stasis ulcerations, in particular above the medial malleolus • Acroangiodermatitis (pseudo-Kaposi sarcoma) • Livedoid vasculopathy ("atrophie blanche"): porcelain-white scars surrounded by punctate telangiectasias and painful ulcerations*
*Need to exclude causes of hypercoagulability/thrombophilia (see Table 105.9).

Table 13.3 Cutaneous signs of chronic venous hypertension. See Figs. 105.4, 105.5 and 105.7.

Fig. 13.8 Autosensitization dermatitis in a patient with venous ulceration. Note the involvement of the extensor surfaces of the upper extremities in this patient with an allergic contact dermatitis to neomycin, as well as stasis dermatitis and venous ulceration. *Courtesy Jean L. Bolognia, MD.*

Often stasis dermatitis appears when lipodermatosclerosis develops (see Fig. 105.5). Erythema and scaling are most pronounced around the inner malleoli, but may extend to involve the entire distal lower extremity. Stasis dermatitis is markedly pruritic, as evidenced by multiple excoriations which lead to oozing and crusting. Episodes of vesiculation occur infrequently, always raising the suspicion of superimposed contact sensitization. Chronic lesions of stasis dermatitis invariably exhibit considerable lichenification. Once ulcers form, stasis dermatitis frequently becomes highly irritated, oozing, and erosive (see Fig. 105.4).

Contact sensitization often leads to secondary dissemination. Patches of eczema arise in a strikingly symmetric distribution pattern, particularly on the anterior aspect of the contralateral leg, the anterior thighs, and the extensor surface of the upper extremities (Fig. 13.8); lesions may generalize to involve the trunk and face.

Downloaded for Anonymous User (n/a) at Egyptian Knowledge Bank from ClinicalKey.com by Elsevier on March 10, 2024. For personal use only. No other uses without permission. Copyright ©2024. Elsevier Inc. All rights reserved.

Pathology

The histologic features of eczema, including stasis dermatitis, vary according to the stage of the lesion. In *acute* eczematous eruptions, intraepithelial edema (spongiosis) predominates, with focal fluid accumulation as micro- or macrovesicles, accompanied by lymphocytes in a perivascular array in the superficial dermis and exocytosis of lymphocytes into the epidermis. There is usually focal parakeratosis. In the *subacute* phase, spongiosis is still evident, but may be more subtle and intraepidermal vesicles are less prominent. The epidermis thickens variably and parakeratosis is present focally (see Fig. 13.7D). Lymphocytes persist in the dermis and epidermis. In both acute and subacute stages, edema may be present in the papillary dermis.

In the *chronic* phase, thickening of the epidermis (acanthosis) is more pronounced and it occurs in a regular, psoriasiform pattern or, more often, has a more irregular profile. Inflammation and spongiosis are mild and may be absent. Changes in the granular layer are variable, from thickening, simulating lichen simplex chronicus, to thinning, where the pattern more closely approaches psoriasis; the latter is seen more often in nummular eczema. Ascribing a specific cause of the dermatitis based upon this constellation of histologic findings is impossible.

In stasis dermatitis, biopsy specimens display the histologic features just outlined, as well as signs of venous hypertension: an increased number of capillaries which are dilated and surrounded by cuffs of fibrin, hemosiderin deposits, and hyperplastic (and at times thrombotic) venules (Fig. 13.9). The increase in vessel number can be marked so as to mimic a vascular proliferation. In later stages, there is fibrosis of the dermal connective tissue and sclerosis of the adipose tissue (see Ch. 100).

Differential diagnosis

Stasis dermatitis is a straightforward diagnosis if the cutaneous signs of venous hypertension are present (see Table 13.2). Difficulties may arise in differentiating the individual etiologic components, such as asteatotic eczema and irritant or allergic contact dermatitis. Patch testing is required to exclude the latter. Plaques of stasis dermatitis may be mistaken for nummular eczema, psoriasis, or even mycosis fungoides.

Treatment

The major aim of therapy is the management of venous hypertension – a complex goal which is reviewed in Chapter 105. Basic measures include the regular use of adequate compression bandages or stockings to improve venous return, lifestyle changes, and exercise of the calf muscles. If indicated, surgical strategies are undertaken (see Ch. 155).

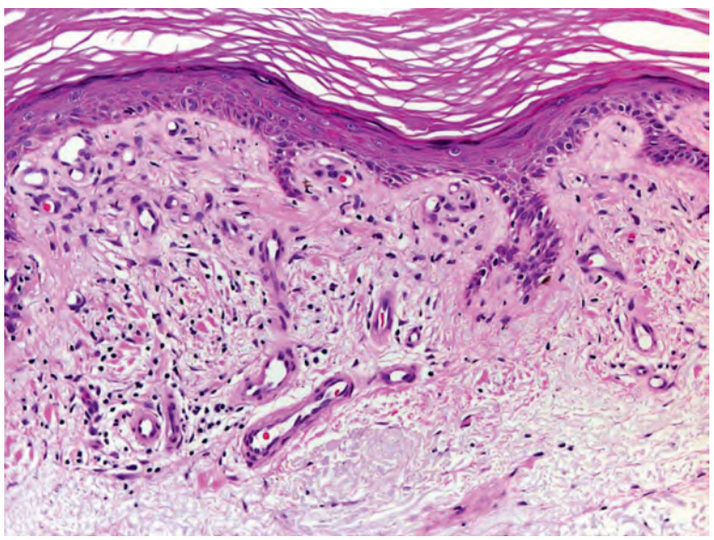

Fig. 13.9 Stasis dermatitis – histologic features. Orthohyperkeratosis and minimal spongiosis in the epidermis. There is an increased number of blood vessels surrounded by a fibrin cuff in a slightly fibrotic papillary dermis. Note also extravasation of erythrocytes and a mild lymphocytic infiltrate. *Courtesy Lorenzo Cerroni, MD.*

However, these surgical approaches do not replace the need for ongoing compression therapy. Topical treatment is the same as for other types of eczemas: judicious use of topical corticosteroids and emollients.

Dyshidrotic Eczema

Synonyms: ▪ Pompholyx (larger vesicles and bullae) ▪ Acute and recurrent vesicular hand dermatitis

Key features

- Firm, pruritic vesicles of the palms, soles, and lateral and medial aspects of the fingers and toes
- Association with atopic dermatitis and contact dermatitis (allergic and irritant)
- No disturbance of sweat gland function

Introduction

Dyshidrotic eczema is a not-infrequent, chronic, relapsing palmoplantar eczematous dermatosis characterized by firm, pruritic vesicles and bullae. While the vesicles are due to spongiosis within the epidermis, their intact nature is explained by the thick tear-proof horny layer in these sites. Dyshidrotic eczema is not an independent disease entity because it is often a manifestation of other types of eczema, especially atopic dermatitis and irritant or allergic contact dermatitis.

Pathogenesis

Although the formation of vesicles is not linked to sweat gland dysfunction or trapping of sweat within the epidermis (as the term may suggest), hyperhidrosis can be an aggravating factor in some patients. Notably, treatment of hyperhidrosis with onabotulinumtoxin A may ameliorate dyshidrotic eczema[59].

Dyshidrotic eczema is frequently an expression of atopic dermatitis, particularly as a late-stage manifestation. In these patients, its intensity is usually low to moderate with a protracted and relapsing course, and it is accompanied by only a few other signs of atopic dermatitis. Less often, dyshidrotic eczema is a manifestation of acute or subacute allergic contact dermatitis. Flares can also result from exposure to known irritants (see Ch. 15).

Occasionally, administration of IVIg is followed by acute episodes of dyshidrotic eczema. The role of ingestants, in particular nickel and cobalt, has been debated, but improvement with a low-nickel diet (in nickel-sensitive patients with a positive oral provocation test) has been observed. Lastly, flares can also follow periods of emotional stress as well as exposure to hot climates and rarely sunlight.

Clinical features

Dyshidrotic eczema is characterized by symmetric, firm, deep-seated vesicles of the palms, the lateral and medial aspects of the fingers, and less often the soles and toes (Fig. 13.10A). The size of the vesicles may vary from pinhead-sized to several centimeters ("pompholyx"). When smaller lesions are clustered, they have been likened to tapioca pudding (Fig. 13.10B). While the markedly pruritic vesicles initially contain clear fluid, they have a tendency for purulent superinfection. Dyshidrotic eczema resolves via desquamation of characteristically thick scales.

Dyshidrosis lamellosa sicca (also referred to as keratolysis exfoliativa) is a minimal variant which displays no blisters but only small annular collarettes of white scale (see Fig. 39.13).

Pathology

Histologically, a spongiotic dermatitis is seen with the formation of micro- and macrovesicles within the epidermis (Fig. 13.10C). There is no association with sweat glands.

Differential diagnosis

Inflammatory tinea manuum and pedis, scabies, and palmoplantar pustular psoriasis need to be considered as well as dyshidrosiform pemphigoid, dyshidrotic cutaneous T cell lymphoma, erythema

Downloaded for Anonymous User (n/a) at Egyptian Knowledge Bank from ClinicalKey.com by Elsevier on March 10, 2024. For personal use only. No other uses without permission. Copyright ©2024. Elsevier Inc. All rights reserved.

Fig. 13.10 Dyshidrotic eczema – clinical and histopathologic features. A Firm vesicles are seen along the side of the thumb and thenar eminence. Some of them are deep-seated. **B** Clusters of tiny vesicles and annular collarettes of scale where the vesicles have ruptured superimposed on plaques of dermatitis. **C** Histologically, spongiosis within the epidermis is accompanied by macrovesicles; the thick stratum corneum points to an acral location. *A, Courtesy Louis A. Fragola, Jr, MD; B, C, Courtesy Lorenzo Cerroni, MD.*

multiforme, fixed drug eruption, and, in children, infantile acropustulosis. Distinguishing between an id reaction involving the palms or soles and dyshidrotic eczema can sometimes be difficult and some clinicians view them as overlapping entities.

Treatment

Topical emollients and corticosteroids are the mainstay of treatment. Other topical treatments such as calcineurin inhibitors, retinoids, and PUVA (bath > systemic) may also be helpful. An underlying allergic or irritant contact dermatitis needs to be considered and addressed. In chronic relapsing or recalcitrant cases, systemic therapy (e.g. retinoids, oral corticosteroids, or other immunosuppressants such as cyclosporine) may be considered[60].

Infectious Eczematous Dermatitis

This entity is regarded as an eczematous reaction to a localized infection with purulent drainage, most often due to *Staphylococcus* or *Streptococcus* spp. It is thought to result from a sensitization to bacterial antigens. Clinically, pustules and vesicles spread from an infectious nidus. More advanced stages are characterized by crusting, scaling, and oozing[61]. In children, the nares, ears, and face are the most common sites of involvement, whereas in adults, the distal lower extremities are most often affected. Milder forms can be treated with open wet dressings, topical antibiotics, topical corticosteroids, and emollients whereas more severe disease usually requires the addition of oral antibiotics and sometimes oral corticosteroids.

Infectious eczematous dermatitis should be distinguished from eczema due to autosensitization, in which lesions develop at a distance from the primary site. Lastly, this disease should not be confused with HTLV-associated infective dermatitis (see above).

Juvenile Plantar Dermatosis

Synonyms: ▪ Atopic winter feet ▪ Forefoot dermatitis ▪ Dermatitis plantaris sicca ▪ Moon-boot foot syndrome ▪ Sweaty sock dermatitis

Key features

- Dry, scaly, glazed and fissured plantar surface of the forefoot
- Prepubertal children are affected
- Association with atopy and exogenous factors

Introduction

The feet are a fairly common site for various eczematous dermatoses (Table 13.4). Juvenile plantar dermatosis is a characteristic condition that occurs primarily (but not exclusively) in children with an atopic diathesis.

History

Juvenile plantar dermatosis was first reported by Mackie and Husain[62].

Epidemiology

Juvenile plantar dermatosis occurs in prepubertal children, from the age of 3 years and upwards, when shoes are worn for longer periods of time. It is only occasionally seen in adults. There is seasonal variation, with worsening during the winter, and boys are affected slightly more often than girls.

Pathogenesis

An atopic disposition is clearly a risk factor, but exogenous factors play an equally important role, including plastic- and rubber-constructed sports shoes that youngsters often wear all day long. The humid environment leads to hydration of the horny layer, making it much less resistant to wear and tear. When the stratum corneum is rubbed off by friction, this leads to a characteristic glazed and thinned appearance of the skin. As involved areas become xerotic, cracks are formed. The inherently dry skin of atopic individuals may be a predisposing factor. Adults have a much thicker horny layer of their plantar skin and are thus less at risk of developing the condition.

Clinical features

The balls of the feet and the toe pads exhibit strikingly symmetrical changes: fairly well demarcated shiny, reddish, tender, dry lesions with

Downloaded for Anonymous User (n/a) at Egyptian Knowledge Bank from ClinicalKey.com by Elsevier on March 10, 2024. For personal use only. No other uses without permission. Copyright ©2024. Elsevier Inc. All rights reserved.

DIFFERENTIAL DIAGNOSIS OF DERMATITIS OF THE FOOT
Allergic contact dermatitis (footwear dermatitis)
• Dermatitis of the dorsal aspects of the feet and toes (allergen contained in the "top" of the shoes) • Dermatitis of the weightbearing areas of the soles (allergens contained in the sole of the shoes) • Most common allergens: dichromate, rubber accelerators, colophony, dyes, formaldehyde resins; also consider topical antibiotics, e.g. bacitracin • Association with atopy and hyperhidrosis • Distinguish from sock and stocking dermatitis where lesions extend more proximally (popliteal area, thighs) – most common allergen is azo dyes
Tylosis
• Mechanically induced hyperkeratosis, dryness, and fissuring • Predilection sites: heels and weightbearing areas of the soles • In middle-aged to elderly individuals • Associated with obesity and hyperhidrosis
Acquired plantar keratoderma (keratoderma climactericum)
• Same as tylosis but more intense • Typically occurs in women over the age of 45 years, but may also be seen in men • Similar lesions may appear on palms
Juvenile plantar dermatosis
See section in this chapter
Tinea pedis (athlete's foot)
• Dermatophyte infections of the plantar skin are usually accompanied by involvement of the interdigital spaces as well as lateral aspects of the foot • Often symmetric, accompanied by onychomycosis • Lesions on the lateral and dorsal aspects of the feet have well-demarcated circinate borders • Occasionally vesicular variant
Psoriasis (see Ch. 8)
• Well-circumscribed plaques or diffuse erythema with thick adherent scales, dryness, and fissuring • Psoriatic plaques found elsewhere on the body • Nail involvement, e.g. pitting and oil-drop changes
Dyshidrotic eczema
See section in this chapter
Recurrent focal palmar and plantar peeling (keratolysis exfoliativa)
• Probably represents a mild form of dyshidrosis • Dry, circinate, thin scales of palms and soles • Vesicles are absent
Pustulosis of the palms and soles (see Ch. 8)
• A neutrophilic dermatosis, possibly related to pustular psoriasis • Chronic course with crops of non-pruritic, short-lived, superficial pustules, particularly of the instep • Yellow–brown macules admixed with pustules
Sézary syndrome (see Ch. 120)
• Palms and soles are tender and exhibit scaling, which can be quite thick • Associated with hypertrophic onychodystrophy and erythroderma
Other
• Atopic dermatitis • Irritant contact dermatitis (e.g. due to occlusive footwear) • Palmoplantar lichen planus • Pityriasis rubra pilaris • Acrokeratosis paraneoplastica • Keratoderma blennorrhagicum • Inherited palmoplantar keratodermas (see Ch. 58) • Palmoplantar keratoderma associated with hypothyroidism • Crusted scabies

Table 13.4 Differential diagnosis of dermatitis of the foot.

some scaling (Fig. 13.11), and often accompanied by painful cracks and fissures. The dorsa of the feet, the interdigital spaces, and the instep are typically spared. Less often, similar lesions are found on the hands.

Fig. 13.11 Juvenile plantar dermatosis in a child. Erythema and scaling of the plantar surface of the great toes and fifth toes as well as the ball of the foot bilaterally. Note the glazed appearance of the skin of the left foot. *Courtesy Kalman Watsky, MD.*

Pathology

Histologically, the features of a chronic eczematous dermatitis are seen (see section "Stasis dermatitis").

Differential diagnosis

Juvenile plantar dermatosis needs to be distinguished from *allergic contact dermatitis* to chemicals contained in leather (e.g. chromates, dyes) or rubber. However, the latter is uncommon in children and, if present, often involves the dorsa of the feet as well. *Tinea pedis* is equally uncommon in children, and the interdigital spaces are usually predominantly affected. Patch testing and KOH preparations may help in establishing the diagnosis.

Treatment

Juvenile plantar dermatosis is a chronic but self-limiting condition. Patients should be advised to avoid wearing impermeable socks and shoes, and the application of emollients, keratolytics, and/or paraffin-type ointments is beneficial. When shoes are removed, socks, if damp, should also be removed and replaced by dry socks.

Diaper Dermatitis

Key features

- Frequently, an irritant dermatitis of the diaper area due to occlusion and prolonged exposure to urine and feces
- Secondary infection with *Candida albicans* often occurs
- May be associated with seborrheic dermatitis and psoriasis

Epidemiology

Diaper dermatitis develops in at least 50% of infants, and it is responsible for a considerable percentage of dermatologic consultations in infants and toddlers. Seborrheic dermatitis is a predisposing factor.

Pathogenesis

Diaper dermatitis is the cumulative result of several factors, in particular dampness and exposure to urine and feces. In the past, ammonia derived from the urea in urine was held as primarily responsible for diaper dermatitis. More recently, the blame has been placed on the (alkaline) pH of the urine and the role of fecal bacteria. Enzymes produced by fecal bacteria, as well as residual pancreatic proteases and lipase in the stool, act as irritants and these enzymes are also activated in the

Downloaded for Anonymous User (n/a) at Egyptian Knowledge Bank from ClinicalKey.com by Elsevier on March 10, 2024. For personal use only. No other uses without permission. Copyright ©2024. Elsevier Inc. All rights reserved.

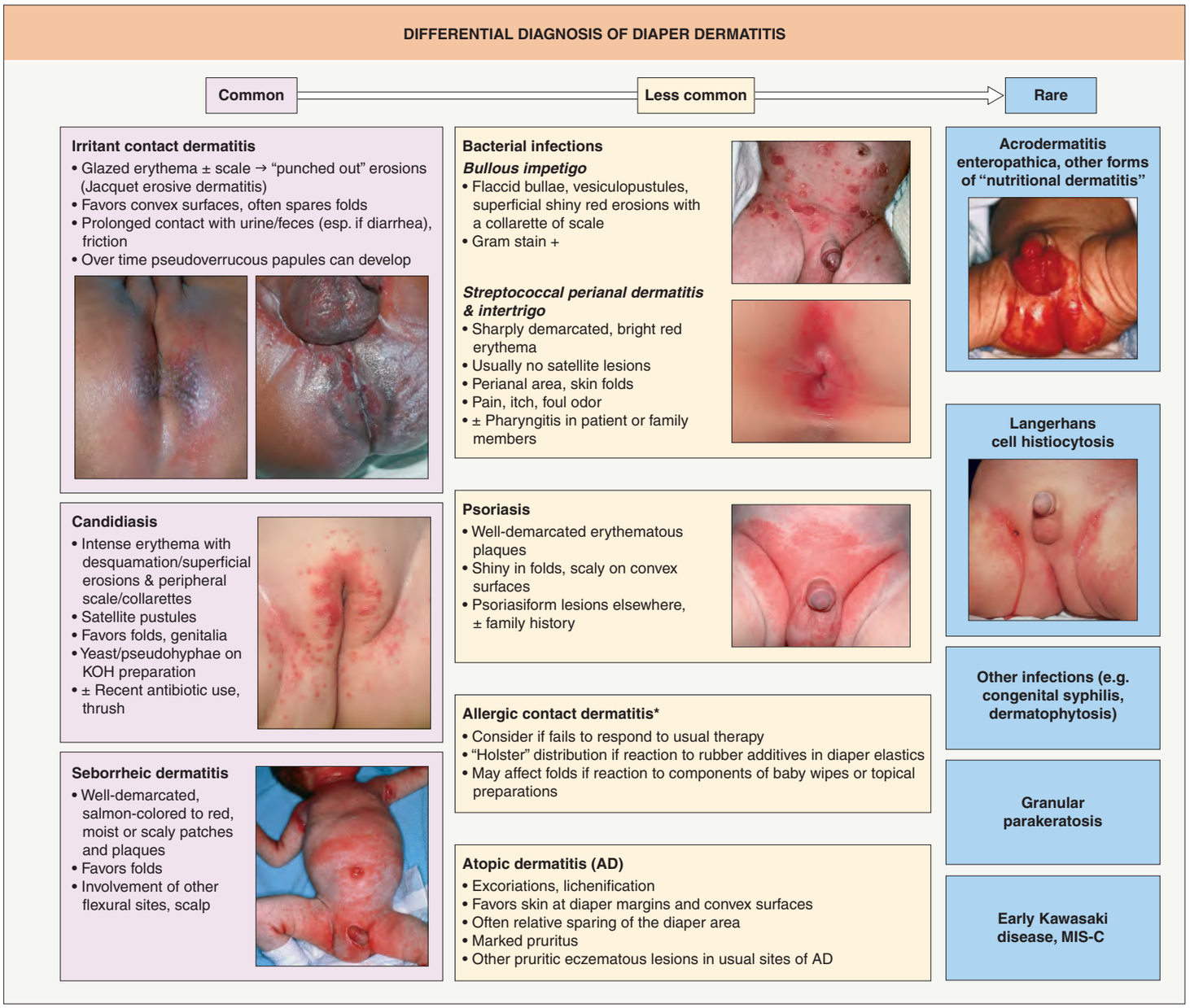

Fig. 13.12 Differential diagnosis of diaper dermatitis. While the most common etiologies are irritant contact dermatitis, cutaneous candidiasis and seborrheic dermatitis, patients often have a combination with one disorder superimposed on another. The spectrum of "erosive papulonodular dermatosis" due to chronic irritation in the diaper area includes granuloma gluteale infantum, pseudoverrucous papules, and Jacquet erosive dermatitis. Discrete papules or nodules are seen in scabies, whereas congenital syphilis often presents with erosions and even ulcerations, MIS-C, SARS-CoV-2-related multisystem inflammatory syndrome in children. *Potential allergens include sorbitan sesquioleate (an emulsifier in diaper balms), fragrances, disperse dyes, rubber additives (e.g. mercaptobenzothiazole), and preservatives in baby wipes (e.g. iodopropynyl butylcarbamate). *Insets: Courtesy Robert Hartman MD; Julie V. Schaffer, MD.*

alkaline milieu[63,64]. In addition, ureases are produced by fecal bacteria, resulting in a further increase of the urinary pH. This explains why diaper dermatitis is more likely to appear in cow milk-fed than in breast-fed infants: cow milk formulas are colonized by a greater number of urease-producing bacteria[65].

Prolonged use of diapers, dampness, and the factors detailed above lead to the breakdown of the horny layer barrier function. An alkaline pH also facilitates the development of secondary *C. albicans* infection.

As diaper dermatitis tends to be most prominent on the inner parts of the thighs, genitalia, and buttocks, friction between the skin and the diaper material likely acts as a physical factor that leads to further irritation. In addition, chemical constituents of the diaper and/or topical preparations and baby wipes may lead to contact sensitization.

Clinical features

Diaper dermatitis is strictly confined to the diaper area, presenting with mild to pronounced erythema, erosions, and scaling. In the common form due to irritant contact dermatitis, genitocrural folds are typically spared. Depending on whether there is a secondary infection or an underlying dermatosis (e.g. seborrheic dermatitis, psoriasis), the clinical picture can vary (Fig. 13.12).

Differential diagnosis

The differential diagnosis is outlined in Fig. 13.12.

Treatment

In the acute phase, mild corticosteroid preparations are helpful. Topical imidazole creams are added for secondary infection with *Candida* spp. The major goal of long-term management is avoidance of the causative factors. Frequent changing of highly absorbent disposable diapers is associated with a lower incidence and severity of diaper dermatitis, and it leads to a more physiologic pH[66]. Emollients containing white paraffin (Vaseline®) or soft zinc pastes provide both protective and soothing effects.

Additional figures available in our eBook (see inside front cover for access code).

Downloaded for Anonymous User (n/a) at Egyptian Knowledge Bank from ClinicalKey.com by Elsevier on March 10, 2024. For personal use only. No other uses without permission. Copyright ©2024. Elsevier Inc. All rights reserved.

REFERENCES

1. Unna PG. Das seborrhoische Ekzem. *Monatsschr Prakt Dermatol*. 1897;6:827–846.
2. Shuster S. The aetiology of dandruff and the mode of action of therapeutic agents. *Br J Dermatol*. 1984;111: 235–242.
3. Faergemann J. Management of seborrheic dermatitis and pityriasis versicolor. *Am J Clin Dermatol*. 2000;1: 75–80.
4. Xu J, Saunders CW, Hu P, et al. Dandruff-associated *Malassezia* genomes reveal convergent and divergent virulence traits shared with plant and human fungal pathogens. *Proc Natl Acad Sci USA*. 2007;104:18730–18735.
5. Arsic Arsenijevic VS, Milobratovic D, Barac AM, et al. A laboratory-based study on patients with Parkinson's disease and seborrheic dermatitis: the presence and density of Malassezia yeasts, their different species and enzymes production. *BMC Dermatol*. 2014;14:1–9.
6. Nenoff P, Krüger C, Mayser P. Kutane. Malassezia-Infektionen und Malassezia-assoziierte Dermatosen: ein Update [Cutaneous Malassezia infections and Malassezia associated dermatoses: an update]. *Hautarzt*. 2015;66:465–486.
7. Faergemann J. *Pityrosporum* species as a cause of allergy and infection. *Allergy*. 1999;54:413–419.
8. Gupta AK, Kohli Y, Summerbell RC, et al. Quantitative culture of *Malassezia* species from different body sites of individuals with or without dermatoses. *Med Mycol*. 2001;39:243–251.
9. Nakabayashi A, Sei Y, Guillot J. Identification of *Malassezia* species isolated from patients with seborrhoeic dermatitis, atopic dermatitis, pityriasis versicolor and normal subjects. *Med Mycol*. 2000;38:337–341.
10. Moreno-Coutiño G, Sánchez-Cárdenas CD, Bello-Hernández Y, et al. Isolation of *Malassezia* spp. in HIV-positive patients with and without seborrheic dermatitis. *Ann Bras Dermatol*. 2019;94:527–531.
11. Ostlere LS, Taylor CR, Harris DW, et al. Skin surface lipids in HIV-positive patients with and without seborrheic dermatitis. *Int J Dermatol*. 1996;35:276–279.
12. McGinley KJ, Leyden JJ, Marples RR, Kligman AM. Quantitative microbiology of the scalp in non-dandruff, dandruff, and seborrheic dermatitis. *J Invest Dermatol*. 1975;64:401–405.
13. Wikramanayake TC, Borda LJ, Miteva M, Paus R. Seborrheic dermatitis-looking beyond Malassezia. *Exp Dermatol*. 2019;28:991–1001.
14. Sanders MGH, Pardo LM, Franco OH, et al. Prevalence and determinants of seborrhoeic dermatitis in a middle-aged and elderly population: the Rotterdam Study. *Br J Dermatol*. 2018;178:148–153.
15. Sullivan AK, Raben D, Reekie J, et al. Feasibility and effectiveness of indicator condition-guided testing for HIV: results from HIDES I (HIV indicator diseases across Europe study). *PLoS ONE*. 2013;8:e52845.
16. Burton JL, Cartlidge M, Cartlidge NEF, Shuster S. Sebum excretion in Parkinsonism. *Br J Dermatol*. 1973;88:263–266.
17. Cowley NC, Farr RM, Shuster S. The permissive effect of sebum in seborrhoeic dermatitis: an explanation of the rash in neurological disorders. *Br J Dermatol*. 1990;122:71–76.
18. Kasteler JS, Callen JP. Scalp involvement in dermatomyositis: often overlooked or misdiagnosed. *J Am Med Ass*. 1994;272:1939–1941.
19. Poindexter GB, Burkhart CN, Morrell DS. Therapies for pediatric seborrheic dermatitis. *Pediatr Ann*. 2009;38:333–338.
20. Kastarinen H, Oksanen T, Okokon EO, et al. Topical anti-inflammatory agents for seborrhoeic dermatitis of the face or scalp. *Cochrane Database Syst Rev*. 2014;19:CD009446.
21. Sparsa A, Boulinguez S, Liozon E, et al. Predictive clinical features of eczema craquelé associated with internal malignancy. *Dermatology*. 2007;215:28–35.
22. Gross P. Nummular eczema. *Arch Dermatol Syphilol*. 1941;44:1060–1077.
23. Rawlings AV, Harding CR. Moisturization and skin barrier function. *Dermatol Ther*. 2004;17:43–48.
24. Ghadially R, Brown BE, Sequeira-Martin SM, et al. The aged epidermal permeability barrier. Structural, functional, and lipid biochemical abnormalities in humans and a senescent murine model. *J Clin Invest*. 1995;95:2281–2290.
25. Rogers J, Harding C, Mayo A, et al. Stratum corneum lipids: the effect of ageing and the seasons. *Arch Dermatol Res*. 1996;288:765–770.
26. Simon M, Bernard D, Minondo AM, et al. Persistence of both peripheral and non-peripheral corneodesmosomes in the upper stratum corneum of winter xerosis skin versus only peripheral in normal skin. *J Invest Dermatol*. 2001;116:23–30.
27. Engelke M, Jensen JM, Ekanayake-Mudiyanselage S, Proksch E. Effects of xerosis and ageing on epidermal proliferation and differentiation. *Br J Dermatol*. 1997;137:219–225.
28. Verdier-Sévrain S, Bonté F. Skin hydration: a review on its molecular mechanisms. *J Cosmetic Dermatol*. 2007;6: 75–82.
29. Bushan M, Cox NH, Chalmers RJG. Eczema craquelé resulting from acute oedema: a report of seven cases. *Br J Dermatol*. 2001;145:355–357.
30. Whitfield A. Lumleian lectures: on some points in the aetiology of skin disease. *Lancet*. 1921;2:122.
31. Hindsen M, Spiren A, Bruze M. Cross-reactivity between nickel and palladium demonstrated by systemic administration of nickel. *Contact Dermatitis*. 2005;53:2–8.
32. Hindsen M, Bruze M, Christensen OB. Flare-up reactions after oral challenge with nickel in relation to challenge dose and intensity and time of previous patch test reactions. *J Am Acad Dermatol*. 2001;44:616–623.
33. Roper SS, Jones HE. An animal model for altering the irritability threshold of normal skin. *Contact Dermatitis*. 1985;13:91–97.
34. Cockayne SE, Gawkrodger DJ. Angry back syndrome is often due to marginal irritants: a study of 17 cases seen over 4 years. *Contact Dermatitis*. 2000;43:280–282.
35. Memon AA, Friedmann PS. "Angry back syndrome": a non-reproducible phenomenon. *Br J Dermatol*. 1996;135:924–930.
36. Bonamonte D, Foti C, Vestita M, et al. Nummular eczema and contact allergy: a retrospective study. *Dermatitis*. 2012;23:153–157.
37. Choi S, Zhu GA, Lewis MA, et al. Dupilumab treatment of nummular dermatitis: a retrospective cohort study. *J Am Acad Dermatol*. 2020;82:1252–1255.
38. Manns A, Hidasa M. La Grenade L. Human T-lymphotropic virus type I infection. *Lancet*. 1999;353:1951–1958.
39. LaGrenade L, Hanchard B, Fletcher V, et al. Infective dermatitis of Jamaican children: a marker for HTLV-I infection. *Lancet*. 1990;336:1345–1347.
40. La Grenade L, Manns A, Fletcher V, et al. Clinical, pathologic, and immunologic features of human T-lymphotrophic virus type I-associated infective dermatitis in children. *Arch Dermatol*. 1998;134:439–444.
41. Carvalho EM, Bacellar O, Porto AF, et al. Cytokine profile and immunomodulation in asymptomatic human T-lymphotropic virus type 1-infected blood donors. *J Acquir Immune Defic Syndr*. 2001;27:1–6.
42. Gonçalves DU, Guedes AC, Proietti AB, et al. Interdisciplinary HTLV-1/2 Research Group. Dermatologic lesions in asymptomatic blood donors seropositive for human T cell lymphotropic virus type-1. *Am J Trop Med Hyg*. 2003;68:562–565.
43. Sweet RD. A pattern of eczema in Jamaica. *Br J Dermatol*. 1966;78:93–100.
44. Walshe MM. Infective dermatitis in Jamaican children. *Br J Dermatol*. 1967;79:229–236.
45. Maloney EM, Hisada M, Palmer P, et al. Human T cell lymphotropic virus type I-associated infective dermatitis in Jamaica: a case report of clinical and biologic correlates. *Pediatr Infect Dis J*. 2000;19:560–565.
46. Bittencourt AL. Adult T-cell leukaemia/lymphoma (ATL) in Bahia, Brazil. *Braz J Infect Dis*. 2005;9:437–438.
47. Sippel K, Mayer D, Ballmer B, et al. Evidence that venous hypertension causes stasis dermatitis. *Phlebology*. 2011;26:361–365.
48. Pillsbury DM. *The pathogenesis of eczema. Proc X Int Congress Dermatol (London, 1952)*. London: British Medical Association; 1953:58.
49. Belisario JC. *The pathogenesis of eczema. Proc X Int Congress Dermatol (London, 1952)*. London: British Medical Association; 1953:3.
50. Peschen M, Lahaye T, Hennig B, et al. Expression of the adhesion molecules ICAM-1, CAM-1, LFA-1 and LA-4 in the skin is modulated in progressive stages of chronic venous insufficiency. *Acta Dermatol Venereol*. 1999;79:27–32.
51. Takase S, Schmid-Schönein G, Bergan JJ. Leukocyte activation in patients with venous insufficiency. *J Vasc Surg*. 1999;30:148–156.
52. Jünger M, Steins A, Hahn M, Hafner HM. Microcirculatory dysfunction in chronic venous insufficiency (CVI). *Microcirculation*. 2000;7:S3–S12.
53. Scurr JH, Coleridge-Smith PD. The microcirculation in venous disease. *Angiology*. 1994;45:537–541.
54. Cheatle T. Venous ulceration and free radicals. *Br J Dermatol*. 1991;124:508.
55. Durmazlar SP, Akgul A, Eskioglu F. Hyperhomocysteinemia in patients with stasis dermatitis and ulcer: a novel finding with important therapeutic implications. *J Dermatolog Treat*. 2009;20:336–339.
56. Tavadia S, Bianchi J, Dawe RS, et al. Allergic contact dermatitis in venous leg ulcer patients. *Contact Dermatitis*. 2003;48:261–265.
57. Machet L, Couhe C, Perrinaud A, et al. A high prevalence of sensitization still persists in leg ulcer patients: a retrospective series of 106 patients tested between 2001 and 2002 and a meta-analysis of 1975–2003 data. *Br J Dermatol*. 2004;150:929–935.
58. Scharfetter-Kochanek K, Schuller J, Meewes C, et al. Das chronisch venöe Ulcus cruris. Pathogenese und Bedeutung des "aggressiven Mikromilieus". *J Dtsch Dermatol Ges*. 2003;1:58–67.
59. Wollina U, Karamfilov T. Adjuvant botulinum toxin A in dyshidrotic hand eczema: a controlled prospective pilot study with left-right comparison. *J Eur Acad Dermatol Venereol*. 2002;16:40–42.
60. Christoffers WA, Coenraads PJ, Svensson Å, et al. Interventions for hand eczema. *Cochrane Database Syst Rev*. 2019;4:CD004055.
61. Yamany T, Schwartz RA. Infectious eczematoid dermatitis: a comprehensive review. *J Eur Acad Dermatol Venereol*. 2015;29:203–208.
62. Mackie RM, Husain SL. Juvenile plantar dermatosis: a new entity? *Clin Exp Dermatol*. 1976;1:253–260.
63. Berg RW, Buckingham KW, Stewart RL. Etiologic factors in diaper dermatitis: the role of urine. *Pediatr Dermatol*. 1986;3:102–106.
64. Buckingham KW, Berg RW. Etiologic factors in diaper dermatitis: the role of feces. *Pediatr Dermatol*. 1986;3:107–112.
65. Yoshioka H, Iseki K, Fujita K. Development and differences of intestinal flora in the neonatal period in breast-fed and bottle-fed infants. *Pediatrics*. 1983;72:317–321.
66. Campbell RL, Seymour JL, Stone LC, et al. Clinical studies with disposable diapers containing absorbent gelling materials: evaluation of effects on infant skin condition. *J Am Acad Dermatol*. 1987;17:978–987.

Downloaded for Anonymous User (n/a) at Egyptian Knowledge Bank from ClinicalKey.com by Elsevier on March 10, 2024. For personal use only. No other uses without permission. Copyright ©2024. Elsevier Inc. All rights reserved.

eFig. 13.1 Adult seborrheic dermatitis of the face and scalp. Note the diffuse scaling of the scalp in addition to erythema of the forehead. *Courtesy Jean L. Bolognia, MD.*

eFig. 13.2 Seborrheic dermatitis of the scalp. Diffuse yellow scales are seen. *Courtesy Julie V. Schaffer, MD.*

eFig. 13.4 Asteatotic eczema (eczema craquelé). A The distal lower extremity has areas of dull erythema that contain a criss-cross pattern of superficial cracks and fissures said to resemble a dried river bed. **B** A close-up of the pattern.

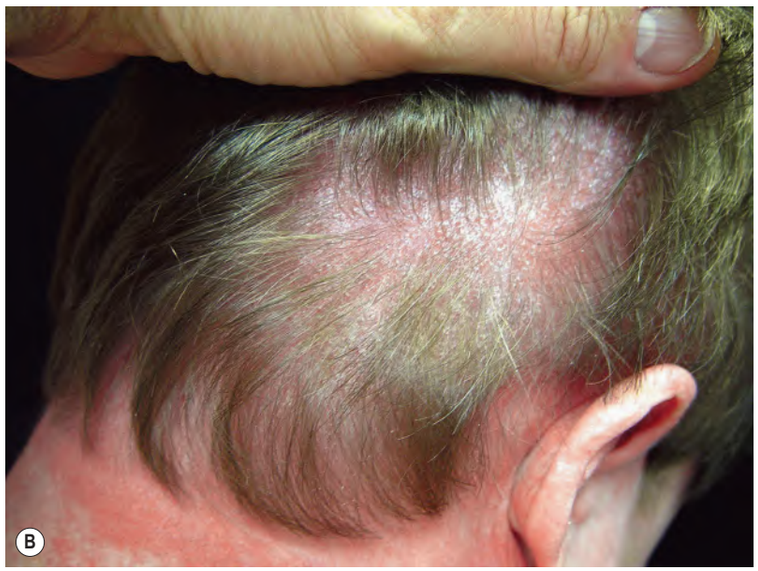

eFig. 13.3 Seborrheic dermatitis-like presentation of Langerhans cell histiocytosis (A) and dermatomyositis (B). Note the extension onto the neck in the patient with dermatomyositis. *A, Courtesy Peter W. Heald, MD; B, Courtesy Jeffrey P. Callen, MD.*

Downloaded for Anonymous User (n/a) at Egyptian Knowledge Bank from ClinicalKey.com by Elsevier on March 10, 2024. For personal use only. No other uses without permission. Copyright ©2024. Elsevier Inc. All rights reserved.

eFig. 13.5 Asteatotic eczema. A It often flares in the winter, arises within areas of xerosis, and is exacerbated by an overuse of soap. **B** When widespread, there can be involvement of the trunk and proximal extremities. Along with the distal lower extremity, the area that surrounds the posterior axillary fold is a common site for asteatotic eczema. *A, Courtesy Kalman Watsky, MD; B, Courtesy Thomas Schwarz, MD.*

eFig. 13.6 Nummular dermatitis. Note the moist "wet" nature of the lesion. *Courtesy Luis Requena, MD.*

eFig. 13.7 Nummular dermatitis. Coin-shaped eczematous plaques with scale-crust. *Courtesy Boni Elewski, MD.*

eFig. 13.8 Nummular dermatitis in a child. The coin-shaped lesions are edematous and have scale-crust. *Courtesy Julie V. Schaffer, MD.*

Downloaded for Anonymous User (n/a) at Egyptian Knowledge Bank from ClinicalKey.com by Elsevier on March 10, 2024. For personal use only. No other uses without permission. Copyright ©2024. Elsevier Inc. All rights reserved.

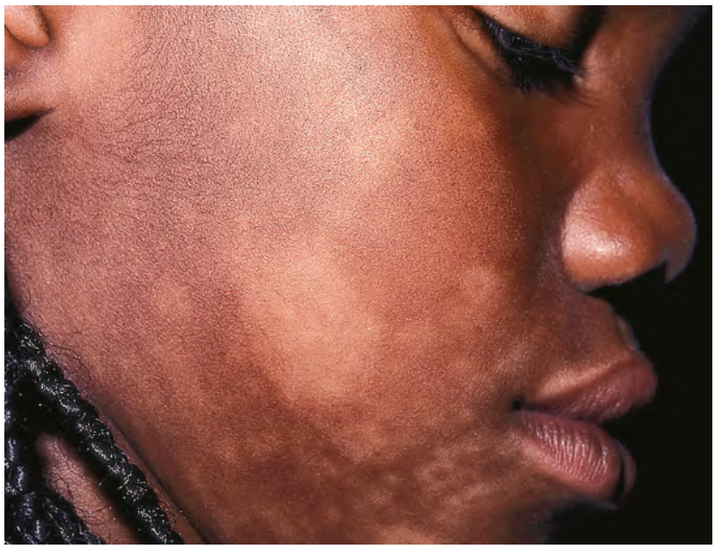

eFig. 13.9 Pityriasis alba. Hypopigmented macules and patches on the cheek of a Black girl. *Courtesy Anthony J. Mancini, MD.*

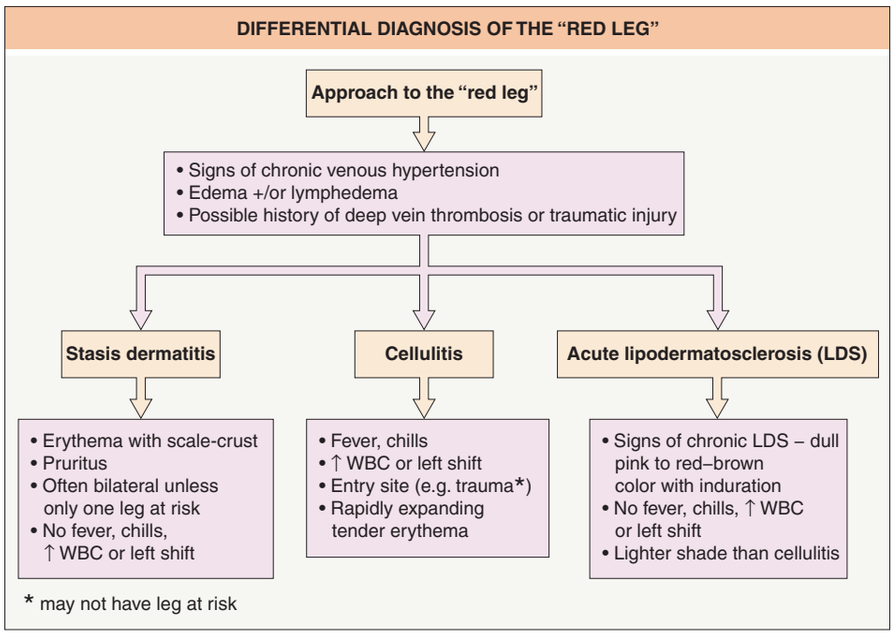

eFig. 13.10 Differential diagnosis of the "red leg". In a patient with chronic lipodermatosclerosis (LDS), it can be difficult to distinguish partially treated cellulitis (e.g. oral antibiotics for several days and no white blood count [WBC] at time of initial presentation) versus superimposed acute LDS. *Courtesy Jean L. Bolognia, MD.*

eFig. 13.11 Dyshidrotic eczema. Firm papules and pseudovesicles on the palms and volar sides of fingers.

Downloaded for Anonymous User (n/a) at Egyptian Knowledge Bank from ClinicalKey.com by Elsevier on March 10, 2024. For personal use only. No other uses without permission. Copyright ©2024. Elsevier Inc. All rights reserved.

eFig. 13.12 Keratotic eczema of the central palm. Some clinicians view this as psoriasis, not dermatitis. A history of repeated rubbing of the site by the third and fourth fingers can sometimes be elicited.

eFig. 13.13 Infectious eczematous dermatitis. Crusting and scaling at the periphery of otitis externa due to *Staphylococcus aureus*.

eFig. 13.14 Acute irritant diaper dermatitis due to prolonged exposure to urine and feces. Glazed erythema with erosions that favors convex surfaces and often spares folds. *Courtesy Julie V. Schaffer, MD.*

eFig. 13.15 Pseudoverrucous perianal papules and nodules (Jacquet dermatitis). This 2-year-old child had frequent exposure to loose stool following a colostomy takedown. *Courtesy Julie V. Schaffer, MD.*

Downloaded for Anonymous User (n/a) at Egyptian Knowledge Bank from ClinicalKey.com by Elsevier on March 10, 2024. For personal use only. No other uses without permission. Copyright ©2024. Elsevier Inc. All rights reserved.